

Clinical presentation of cavernous sinus thrombosis with proptosis and headache

Zohreh Kalbassi: Assistant professor of Pediatric Department, Ali-Asghar Children's Hospital, Iran University of Medical Sciences, Tehran, Iran. z_kalbassi@yahoo.com

Ladan Afsharkhas: (***Corresponding author**) Assistant professor of Pediatric Neurology, Ali-Asghar Children's Hospital, Iran University of Medical Sciences, Tehran, Iran. dr.afsharkhas1@yahoo.com

Alireza Alavi: Assistant Professor of Pediatrics, Ali-Asghar Children's Hospital, Iran University of Medical Sciences, Tehran, Iran. alireza.alavi1358@yahoo.com

Received: 13 Aug 2015 Accepted: 10 Sep 2015

Abstract

This is a report of a case with unilateral cavernous sinus thrombosis due to ipsilateral ethmoid sinusitis. A 10 year old female was admitted in our hospital with severe headache, purulent postnasal discharge, right eye proptosis and third cranial nerve palsy in the same eye. She had history of viral upper respiratory tract infection and then acute otitis media which did not improve with routine medications. Head imaging showed ethmoid sinusitis and cavernous sinus thrombosis. Clinical manifestation was subsided after thirty days aggressive antimicrobial and anticoagulant therapy.

Ethmoid sinusitis can cause cavernous sinus thrombosis. Appropriate management by antibiotic and anticoagulant therapy can prevent neurologic complications and death.

Keywords: Cavernous sinus thrombosis, Sinusitis, Proptosis

Introduction

Dural venous sinuses are important vascular compartments for draining of the brain. They are including sagittal, lateral and cavernous sinuses. Cavernous sinus has complex anatomy and receives venous blood of superior and inferior ophthalmic, sphenoid and middle cerebral veins and finally drain to the jugular veins (1,2). In this system absence of surrounding muscle and valves lead to motion of the bloods in any direction, unresponsiveness to changes in systemic blood pressure and susceptibility to stasis and thrombosis (1). Acquired and inherited coagulation abnormalities, dehydration, medications, neurosurgical procedures, infections (of midface skin, orbits, nose, tonsils, paranasal sinuses and teeth), bacteremia and trauma can damage the cavernous sinus and cause thrombosis (CST) (1,3). Staphylococcus aureus, Streptococcus pneumoniae, gram-negative bacilli and Aspergillus species are more common micro-organisms that lead to infection of CST(4). Clinical manifestations of CST are wide spread from redness of skin around the eyes to severe

headache, proptosis, chemosis, cranial nerves palsy, seizure and loss of consciousness (5). Prompt diagnosis of CST is crucial and in recent decades, contrast – enhanced head computed tomography (CT) scan and magnetic resonance imaging (MRI) have been used with high sensitivity for this purpose (6,7). However, appropriate antimicrobial and anticoagulant therapy (in cases without hemorrhage) is necessary to decrease fatal neurologic complications especially due to central nervous system (CNS) infections (8). In our center, a patient with CST was hospitalized that its source was ipsilateral ethmoid sinusitis.

Case presentation

Patient was a 10 year old girl that admitted to Ali-Asghar Children's Hospital in Tehran; with severe headache and ptosis. She has had a trip to European countries in recent weeks. Her symptoms started 5 days before admission with fever and severe pain in right ear. She used Amoxicillin with diagnosis of acute otitis media. After 3 days gradually other symptoms and signs were present-

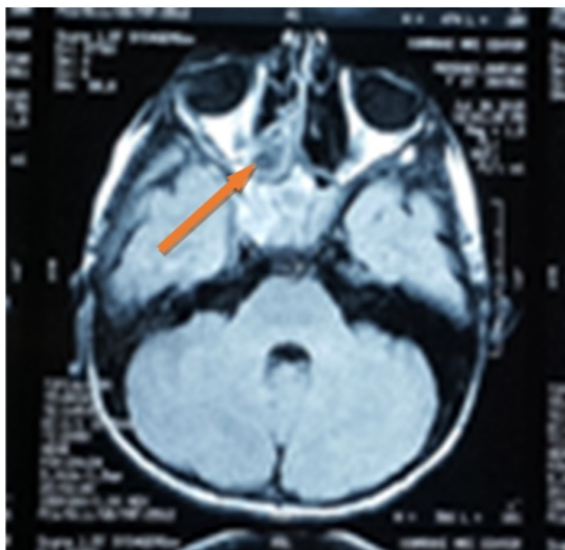


Fig. 1. Opacification of Right Posterior Ethmoidal Sinus and Right CST.

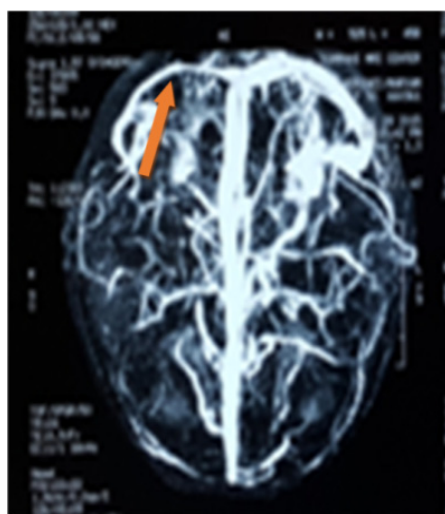
ed including vomiting, occipital and temporal headache, right eye proptosis and sensory loss of right side of the face. At first she was visited in emergency room by a pediatrician and consulted with a child neurologist. In physical examination, vital signs was stable. Temperature was 38.2 degree of centigrade. In right eye examination, there was proptosis, restriction of eye movements to up and lateral sides, mydriasis with reaction to light. Left eye was normal. Sensory loss was detected in V2 and V3 regions of right trigeminal nerve. Other cranial nerves were intact. There was a purulent postnasal discharge in pharynx examination. Deep tendon reflexes, force, tone and bulk of muscles in extremities was in normal limits. There was no abnormality in skin, liver, spleen, lymph nodes

and spine. With suspicion of an important intracranial infection, brain CT scan and after that MRI and magnetic resonance venography (MRV) was requested. Cell blood count (CBC), erythrocyte sedimentation rate (ESR), C Reactive Protein (CRP) and blood culture were carried out. Results (WBC: 13.5×10^3 , segment: 77%, Hb: 12.2g/dl, platelet count: 274×10^3 /ml, ESR=50, CRP=92) suggested a bacterial infection although blood and urine culture results was negative. In brain CT scan, right ethmoidal sinusitis was detected. Intravenous vancomycin and meropenem was ordered for the patient. In brain MRI there was opacification of right posterior ethmoidal sinus and right mastoidal air cells (Fig. 1). MRV detected hypoplasia of right transverse and sigmoid sinuses, asymmetry of right cavernous sinus in comparison with other side and intrasinus narrowing of right internal carotid artery (Fig. 2). According to these findings, diagnosis of cavernous sinus thrombosis was suggested and Enoxaparin was started for the patient. Prothrombin time (PT), partial prothrombin time (PTT) and international normalized ratio (INR) were checked regularly and then medication changed to Warfarin after one week. Antibiotic administration was continued for 21 days. During follow up, ptosis, eye deviation, mydriasis and sensory deficit was improved without sequels, approximately after 30 days.

Discussion

Cavernous sinus thrombosis is a rare event and its mortality -even with recent new antibiotics regimens - is high and recovery may not be complete. Infection of paranasal sinuses are common cause of CST specially ethmoid and sphenoid sinuses

(A)



(B)

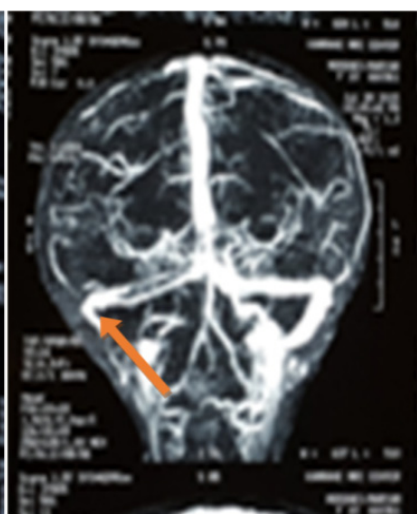

Fig. 2. Hypoplasia of (A) right transverse and (B) sigmoid sinuses

(5,9). Venous obstruction results in clinical manifestation including headache, fever, periorbital edema, visual impairment and cranial nerves palsy. In some cases ischemic stroke occurs and lead to focal neurologic deficit. If effective treatment not be taken immediately, thrombosis progresses and eye involvement becomes bilaterally that is poor prognostic sign. Altered level of consciousness is widely from lethargy to coma and death follows after this event (1,3,4). In our case main presentation was headache and third cranial nerve palsy with history of prior upper respiratory tract infection. Similar to us, Perri et al (2) reported a 14 year old girl that was ill and unconscious. She had fever and sore throat 2 weeks before admission. In physical examination, there was fever, swollen and chemosis of left upper eye –lid, infected tonsils and intermittent chill. After few days patient died and in her autopsy purulent thrombophlebitis of left cavernous sinus, purulent meningitis and purulent sinusitis (left ethmoid, left sphenoid and left maxillary sinuses) was detected. However, in our case because of prompt diagnosis and treatment with antibiotic and anticoagulant drugs, spreading of thrombosis and CNS infection was prevented and patient survived. In another study, Smith et al (7) evaluated 12 children with CST that all of them survived and 3 cases had some permanent neurologic complications. Sensitivity of brain MRI and CT scan (both with contrast-enhancement) was 100%. In a case that was reported by Jones et al (10), patient with diagnosis of rheumatoid arthritis was under treatment of methotrexate for 3 years. She was admitted with right eye proptosis and respiratory distress. In past medical history, she had a four day facial pain due to dental infection. Cavernous sinus thrombosis (CST), bilateral internal jugular thrombosis was detected by imaging. She was treated by intravenous clindamycin and meropenem adjunct with anticoagulant therapy and discharged.

Conclusion

Occurrence of URI infection, headache, fever,

proptosis and cranial nerve palsy should highlight physician to have in his or her corner of mind diagnosis of CST and then perform appropriate imaging, medications and supportive care to save the patient.

Conflicts of interest: None declared.

References

1. Swaiman K F, Ashwal S, Ferriero D M , Schor N F. Swaiman's Pediatric Neurology Principles and Practice 5th ed. 2012; part 14:1419-1421.
2. Perry EB. Cavernous sinus thrombosis: case report. J National Med Ass.1933;25(1):6.
3. Dlamini N, Billingham L, Kirkham F J. Cerebral Venous Sinus (Sinovenous) Thrombosis in Children. Neurosurg Clin N Am. 2010; 21(3-5): 511–527.
4. Watkins LM, Pasternack MS, Banks M. Bilateral cavernous sinus thromboses and intraorbital abscesses secondary to Streptococcus milleri. Ophthalmology. 2003;110(3):569-745. Komatsu H, Matsumoto F, Kasai M, Kurano K, Sasaki D, Ikeda K. Cavernous sinus thrombosis caused by contralateral sphenoid sinusitis: a case report. Head Face Med. 2013;9(9):1-5.
6. Tang Y, Booth T, Steward M, Solbach T, Wilhelm T. The imaging of conditions affecting the cavernous sinus. Clin Radiol. 2010 Nov. 65(11):937-45.
7. Smith D, Licht D, Vossough A, Vorona G. Pediatric Cavernous Sinus Thrombosis: A Case Series and Review of the Literature. Neurology, 2015; 84(14) Supp.P.6.225.
8. Coutinho JM, Ferro JM, Canhão P, Barinagarrementeria F, Bousser MG, Stam J. Unfractionated or low-molecular weight heparin for the treatment of cerebral venous thrombosis. Stroke. 2010; 41(11): 2575-80
9. Sébire G, Tabarki B, Saunders DE, Leroy I, Liesner R, Saint-Martin C, et al. Cerebral venous sinus thrombosis in children: risk factors, presentation, diagnosis and outcome. Brain. 2005; 128(Pt 3):477-89.
10. RG Jones, B Arnold. Sudden onset proptosis secondary to cavernous sinus thrombosis from underlying mandibular dental infection. BMJ Case Reports. 2009; 2009:bcr0320091671.