

Co-existence of Type 1 Diabetes Mellitus and Nephrotic Syndrome with Membranous Glomerulonephritis in a 6-Year Old Boy: Report of a Case

Hasan Otukesh: Department of Pediatric Nephrology, Ali Asghar Children's Hospital, Iran University of Medical Sciences, Tehran, Iran.

Ala Torabi: Tehran University of medical Sciences, Tehran, Iran.

Rozita Hoseini: (*Corresponding author) Department of Pediatric Nephrology, Ali Asghar Children's Hospital, Iran University of Medical Sciences, Tehran, Iran. rozitahoseini@yahoo.com

Parnian Kheirkhah Rahimabad: Department of Pediatric Nephrology, Ali Asghar Children's Hospital, Iran University of Medical Sciences, Tehran, Iran.

Mitra Mehrazma: Department of Pathology, Ali Asghar Children's Hospital, Iran University of Medical Sciences, Tehran, Iran.

Received: 25 July 2016

Accepted: 20 May 2016

Abstract

Background: Nephrotic syndrome and type 1 diabetes mellitus are two common chronic conditions in children. Co-existence of these conditions is an extremely rare finding.

Case presentation: This report presents a 6-year-old boy who was diagnosed with nephrotic syndrome five years ago and type 1 diabetes mellitus in infancy. Renal biopsy showed membranous glomerulonephritis, which is a rare histopathology underlying nephrotic syndrome in children.

Conclusion: Co-existence of nephrotic syndrome and type 1 diabetes mellitus may suggest a mutual immunological basis for both conditions.

Keywords: Type 1 diabetes mellitus, Nephrotic syndrome, Membranous glomerulonephritis

Introduction

Nephrotic syndrome (NS) is characterized by massive proteinuria, hypoalbuminemia, hyperlipidemia and edema (1, 2). Underlying conditions ranging from primary to systemic renal disease can lead to NS with variable histopathological patterns (3, 4). Minimal change disease (MCD) and focal segmental glomerulosclerosis (FSGS) are the two most common histopathological patterns seen in children with NS (5). Membranous glomerulonephritis (MGN) is rarely the underlying pathological pattern of NS in children (3).

The simultaneous occurrence of NS and type 1 diabetes mellitus (T1DM) is extremely rare. Some previous cases have been reported for the co-occurrence of steroid sensitive nephrotic syndrome (SSNS) and T1DM in children (6,7). The underlying histopathological pattern in these was MCD in almost all cases (6,7). The present study reports an unusual case of the co-existence of T1DM and

SSNS with membranous glomerulonephritis (MGN) in a 6-year-old Caucasian male. To the best of our knowledge, this is the first case of co-existence of T1DM and MGN.

Case report

A 6-year-old Caucasian boy with a 5-year history of SSNS was admitted to Ali Asghar Children's Hospital. He was diagnosed with T1DM at 13 days of age. He was being treated with insulin (5 units NPH, 5 units regular twice daily) and prednisolone (10 mg twice daily). He had uncontrollable blood sugar levels while taking prednisolone. Following tapering, he suffered multiple recurrences of SSNS.

In the light microscopy evaluation with silver staining, all of the glomeruli showed a thick glomerular basement membrane (GBM) with holes and spikes (Figure 1). Immunofluorescence revealed granular capillary wall deposits of IgG,

IgM and C3. There was no segmental or global sclerosis or chronic tubulointerstitial changes. There was no evidence of diabetic nephropathy. Based on the clinical and histopathological findings, a diagnosis of idiopathic MGN was made.

Discussion

Nephrotic syndrome is a well-recognized and common illness in childhood characterized by massive proteinuria, hypoalbuminemia, hyperlipidemia and edema (1,2). NS can be classified into primary, secondary, and congenital subtypes (2). Primary idiopathic NS is the most common form in children and occurs without previous disease (2,8). There are different histopathological patterns for primary NS, including MCD and FSGS (3,5). Although MCD is reported to be the most common histological variant in children with NS, the incidence of FSGS appears to be increasing (3,5). Other histological variants include membranoproliferative glomerulonephritis (MPGN) and MGN. MGN is a rare histopathological finding in children with NS (3).

NS in patients with T1DM is generally associated with diabetic nephropathy (9); however, proteinuria associated with T1DM becomes apparent at approximately 12 years after onset of T1DM (6). A short duration of T1DM plus a lack of target organ damage (e.g. retinopathy) suggest the existence of a non-diabetic nephropathy and consideration of renal biopsy in this patient (10).

The number of children with SSNS co-existing with T1DM would appear to be higher than estimated than if these diseases have co-occurred in the same child by chance (7); therefore, a mutual immunological basis is suggested for both conditions. T1DM and SSNS might share HLA loci carrying genetic predisposition to both diseases (7, 11).

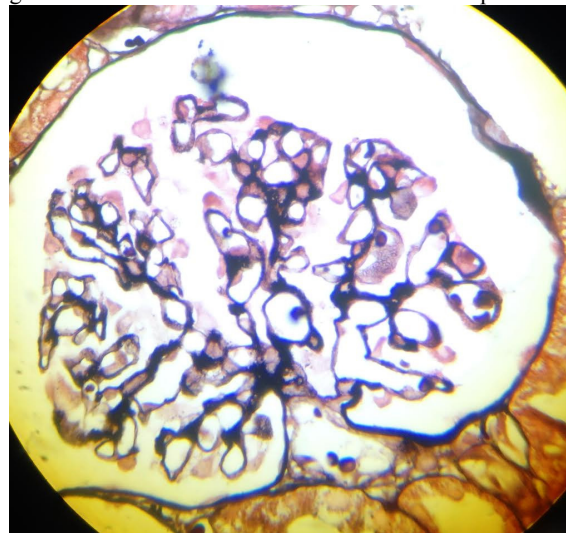
In the previous cases of SSNS coexisting with T1DM in children, MCD was the underlying histopathological pattern in all but one case of immune complex glomerulonephritis, mesangial pattern (6,7,9,12). To the best of our knowledge, this is the first case of MGN-related SSNS in a child with type 1 diabetes.

Conflicts of interest: None declared.

References

1. Srivastava RN. 50 years of nephrotic syndrome in children, and hereafter. *Indian pediatr.* 2013;50(1): 107-10.
2. Safaei AA, Maleknejad S. Clinical and laboratory findings and therapeutic responses in children with

Fig. 1. Microscopic silver-stained specimen showing thick glomerular basement membrane with holes and spikes



nephrotic syndrome. *Indian J Nephrol.* 2010;20(2): 68-71.

3. Obiagwu PN, Aliyu A, Atanda AT. Nephrotic syndrome among children in Kano: a clinicopathological study. *Nigerian J Clin Prac.* 2014;17(3):370-4.
4. de Seigneux S, Martin PY. Management of patients with nephrotic syndrome. *Swiss Med Weekly.* 2009;139(29-30):416-22.
5. Al Salloum AA, Muthanna A, Bassrawi R, Al Shehab AA, Al Ibrahim A, Islam MZ, et al. Long-term outcome of the difficult nephrotic syndrome in children. *Saudi J kid Dis Trans.* 2012;23(5):965-72.
6. Kari JA, El-Desoky SM, Mokhtar G, Jalalah SM. Simultaneous onset of steroid resistant nephrotic syndrome and IDDM in two young children. *BMJ Case Reports.* 2010.
7. Goldman M, Hebert D, Geary DF. Management of steroid-sensitive nephrotic syndrome in children with type 1 diabetes. *Pediatr Nephrol.* 2002;17(5): 351-4.
8. Davin JC, Rutjes NW. Nephrotic syndrome in children: from bench to treatment. *Intl J Nephrol;*2011:372304.
9. Moyses Neto M, Silva GE, Costa RS, Romao EA, Vieira Neto OM, Dantas M. Minimal change disease associated with type 1 and type 2 diabetes mellitus. *Arquivos brasileiros de endocrinologia e metabologia.* 2012;56(5):331-5.
10. Kveder R, Kajtna-Koselj M, Rott T, Bren AF. Nephrotic syndrome in patients with diabetes mellitus is not always associated with diabetic nephropathy. *Nephrol, Dialys Transplant.* 2001;16 Suppl 6:86-7.
11. Rego Filho EA, Mello SF, Omuro AM, Loli JO. [Simultaneous onset of steroid-sensitive nephrotic syndrome and type 1 diabetes]. *J Pediatría.* 2003;79(6):557-60.
12. Robinson LA, Howell DN, Wigfall DR, Foreman

JW. Appearance of immune complex glomerulonephritis following the onset of type I diabetes melli-

tus in a child. Am J Kid Dis. 1997;30(5):713-6.