

## Management of renal abscess in a 5-year-old girl: A case report

**Maryam Boroomand:** Resident of Pediatrics, Children Medical Center, TUMS, Tehran, Iran.

**Mastaneh Moghtaderi:** (\*Corresponding author), Associated Professor of Pediatric Nephrology, Chronic Kidney Disease Research Center, Children Medical Center, Tehran University of Medical Sciences, Tehran, Iran. drmoghtaderi@gmail.com

**Pooya Hekmati:** Pediatric Urologist, Pediatric Urology and Regenerative Medicine Research Center, Children Medical Center, Tehran University of Medical Sciences, Tehran, Iran.

Received: 12 Feb 2017

Accepted: 21 June 2017

### Abstract

Renal abscesses are rare in childhood. They have vague manifestations and any delay in proper diagnosis and treatment could lead to morbidity and mortality. We present a 5-year-old girl with multiple renal abscesses after pyelonephritis that lead to total nephrectomy due to multiple drug resistance.

The renal abscess may have subtle symptoms. Early diagnosis and treatment strongly prevents undue mortality and morbidity. This case highlights the need of timed diagnosis and proper treatment. There must be a clinical suspicion of renal abscess if treatments have not enough effect on clinical condition of patient.

**Keywords:** Acute Pyelonephritis, Renal Abscess, Children

### Background

Renal and perirenal abscess is an uncommon potentially lethal diseases resulting from infection of the kidney or its surroundings like pyelonephritis or from hematogenous spread of another foci (1,2). There may be predisposing conditions like obstructive uropathy or UTI, diabetes mellitus, intravenous drugs abuse, trauma, recent abdominal or urologic operation and immunodepressives used in malignancies or AIDS (3). Clinical manifestations are generally nonspecific such as fever and vague abdominal pain. Elevated erythrocyte sedimentation rate (ESR) and increase of C reactive protein (CRP), leukocytosis and less often positive blood and urine cultures. Therefore delayed definite diagnosis can be quiet common. Gram-negatives mainly *Escherichia coli* are the most common pathogens found in cases following urinary tract infection. Staphylococcal renal abscess (*s. aureus*) are most predominate when the route of infection is haematogenous (2). Differential diagnoses includes emphysematous pyelonephritis, papillary necrosis following acute pyelonephritis, acute malacoplakia, lobar tuberculosis, nephronia, renal cell carcinoma or Wilms' tumour. Therefore, a full diagnostic study is recommended (4). Any delay diagnosis of renal abscess may lead to increase of morbidity and mortality. Nowadays it has been reduced because of the more sophisticated procedures like computed

tomography (CT) scan and magnetic resonance imaging (MRI) scan (1).

Classic treatment of renal abscesses include antibiotics, surgical exploration, incision and drainage when it is necessary, or nephrectomy as the last one. Small renal abscesses can be treated efficiently with the proppare drainage and a full course of intravenous antibiotics (1).

We describe a case of multiple renal abscesses following pyelonephritis that eventually lead to total nephrectomy because of microbial drug resistance.

### Case Presentation

A 5 years old girl was referred to our hospital with abdominal pain and fever from 3 days ago .The pain was periumblical, contineus radiating to left flank. Other symptoms were malaise, anorexia, vomiting, fever and dysuria. She reported long period of constipation and voiding dysfunction lasting several months ago. She did not have history of any urinary tract infection in the past. In physical examination she had left costovertebral angle tenderness, fever and a dimple in upper anal verge. She had received cefexime before admitting in hospital.

Laboratory findings include leukocytosis (25000) with neutrophil predominance, ESR=97, CRP=31, active urine analysis with negative urine and blood culture. Serum immunoglobulin levels

were within normal range, immunodeficiency disorders including late-onset common variable immunodeficiency were unlikely. The biochemistry study was normal. First performed sonography was normal. Ceftriaxon was started at first but as the fever continued beyond 3 days amikacin was added. The fever continued for 7 days, unilateral lymphadenopathy and leukocytosis appeared, ESR raised more, so rheumatologic consultation was requested because of suspicion of Kawasaki disease and IVIG and aspirin was started. Echocardiography was normal. However, the fever did not improved, so renal sonography was repeated that revealed three hypoechoic lesions without vascularity in the upper pole of the left kidney (38×25 mm), lower pole of left kidney (24×10 mm) and subcortical middle lobe of left kidney (9×7 mm) with perinephric liquid accumulation. DMSA scan was shown multiple defects in left kidney. CT angiography of left kidney revealed enlargement and heterogeneity of kidney, fat stranding and inflammation in perinephric area, several lesions with low attenuated in upper pole (44×30 mm) and lower pole (16×9 mm), and also three para-aortic lymphnodes in left renal hilum (6×9 mm) (Figures 1-3.). In VCUG she had grade 3 reflux in left kidney and widening of left pyelocalicial system due to abscess formation. As a result, ceftriaxone was discontinued; meropenem and vancomycin were added to amikacin. But because of no response to medical treatment after urologic consultation nephrectomy was performed. After 6 months follow up BUN, Cr, electrolytes are normal. Constipation and voiding dysfunction improved remarkably.

### Discussion

Renal abscesses occur in all ages and are three times more common in males than in females. These abscesses are walled-off cavities and most of them are unilateral single lesions (77%) and occur in the right kidney more frequently (63%). The incidence of renal abscess in children is unknown (4). Interestingly our patient was female with multiple renal abscesses in her left kidney. Diagnosis of renal abscess is a clinical challenge due to diversity of the source of infection and different pathogenic mechanisms, such as complication of UTI, hematogenous spread of a far infectious foci, or in rare cases of staphylococcal carbuncle proximal kidneys (5,6). Our case had pyuria with negative urine and blood culture. The clinical diagnosis of renal or perinephric abscess should be suspected in a patient with inconsistent signs and symptoms, including prolonged fever

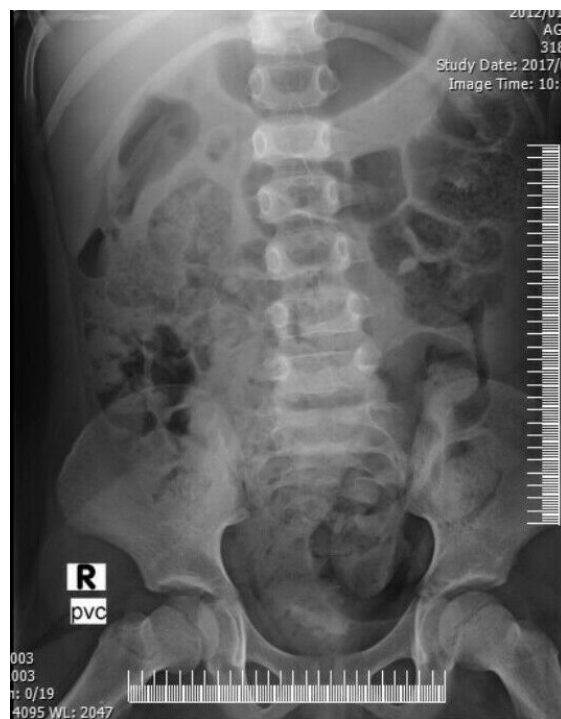

Fig. 1. CT scan

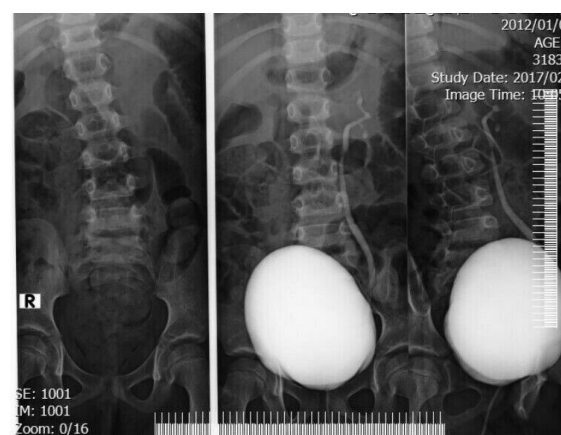


Fig.2. CT scan presenting enlargement of left kidney

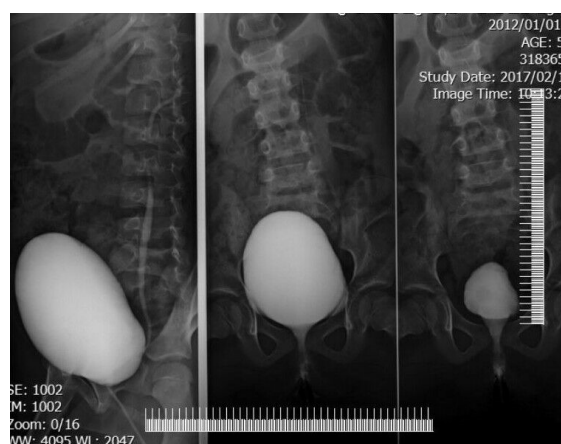


Fig.3. CT scan presenting enlargement of left kidney

and flank pain, and laboratory evidence of chronic inflammation such as elevated ESR and CRP. De-

tection on of renal abscess on imagings ideally computed tomography confirms the diagnosis (7). Our patient had prolong fever, leukocytosis with neutrophilia and elevated ESR, CRP and normal sonography at first. In most of children, the pathogenesis may be associated with an ascending infection superimposed on a pre-existing malformation of urinary tract, particularly vesicoureteral reflux (VUR) (8). She had left VUR (grade 3) but didn't have any history of previous urinary tract infection. Classical treatment of renal abscesses is surgical exploration, incision and drainage, or nephrectomy. In fact, simple invasive treatment appeared in early 1970s, is replaced with more conservative treatments due to the progress in imaging techniques to detect the abscess and also emergence new antibiotics. Small renal abscesses can be effectively treated with the complete drainage and a full course of intravenous antibiotics (9). Large size of abscess, presence of obstructive uropathy, severe vesicoureteral reflux, diabetes, old age, and gas forming organisms are the major factors associated with treatment failure. If there is a large abscess or obstructive uropathy, and no clinical improvement occurs after 48 to 72 hours of appropriate antibiotic therapy nephrostomy should be considered. (1). Our patient received proper antibiotic for about 3 weeks with no improvement, so eventually radical nephrectomy was done. After 6 months follow-up, she has normal blood pressure and renal function test.

### Conclusion

The diagnosis of renal abscess is frequently delayed, and the mortality and morbidity is extensive in most cases. Thus, proper diagnose and treatment is necessary. Renal abscesses should be seriously considered when a patient presents with symptoms of pyelonephritis but and did not response to standard treatments. Sometimes, renal abscess that cannot be treated with roper medical treatments lead to partial or even total nephrectomy.

*Conflicts of interest:* None declared.

### References

- Fernandes RC, Duarte PD. Perinephric and renal abscesses in children: a study of three cases. *Revista do Instituto de Medicina Tropical de São Paulo*. 2002 Dec;44(6):341-4.
- Secil Conkar, Ipek Kaplan Bulut, Sevgi Mir .Renal abscess in a previously healthy 4-year-old girl. *Ped Urol Case Rep* 2016;3(5):170-175 .
- Angel C, Shu T, Green J, Orihuela E, Rodriguez G, Hendrick E. Renal and perirenal abscess in children: proposed physiopathologic mechanisms and treatment algorithm. *Pediatr Surg Int*. 2003;19(1):35-9.
- Fernandes RC, Duarte PD. Perinephric and renal abscesses in children: a study of three cases. *Rev Inst Med Trop S Paulo*. 2002;44(6):341-4.
- Shimizu M, Katayama K, Kato E, Miyayama S, Sugata T, Ohta K. Evolution of acute focal bacterial nephritis into a renal abscess. *Pediatr Nephrol*. 2005;20(1):93-5.
- Chaudhry S, Bolt R. Bilateral renal abscess in a previously healthy 11-yearold girl. *Eur J Pediatr*. 2010;169(11):1423-5.
- Lee SH, Jung HJ, Mah SY, Chung BH. Renal abscesses measuring 5 cm or less: outcome of medical treatment without therapeutic drainage. *Yonsei Med J* 2010 Jul;51(4):569-73..
- Movahedi M, Moin M, Farhoudi A. A comparison between diagnostic clinical tests and herbal geography in allergic patients in tehran and karaj cities. *Iran J Allergy Asthma Immunol* 2000; 1(1): 29-31.
- Khazaei HA, Hashemi SR, Aghamohammadi A, Farhoudi AH, Rezaei N. Common allergens in patients with allergic disorders in Zahedan. *Tabib-E-Shargh* 2003; 4(3): 149-54.
- Chng SY, Goh DY, Wang XS, Tan TN, Ong NB. Snoring and atopic disease: a strong association. *Pediatr Pulmonol*. 2004 Sep 1;38(3):210-6.
- Nabavizadeh S, Yazdanpanah S, Abidi H, Zoladl M. The incidence of Common Allergens in Patients with Allergic Rhinitis Referred to Shahid Mofatteh Clinic, Yasuj, Iran. *Armaghane danesh*. 2013;18(9): 736-745.
- Dogru M1, Evcimik MF2, Calim OF3. Does adenoid hypertrophy affect disease severity in children with allergic rhinitis?. *Eur Arch Otorhinolaryngol*. 2017 Jan;274(1):209-213.